

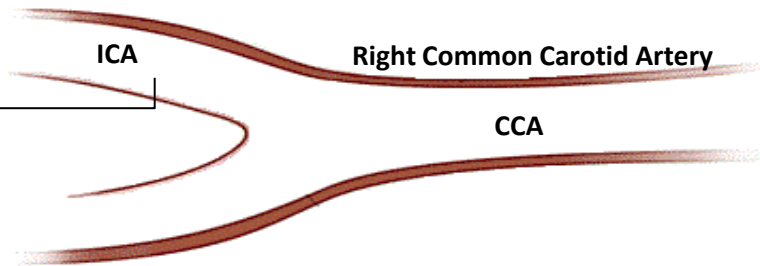


## Carotid Duplex Report

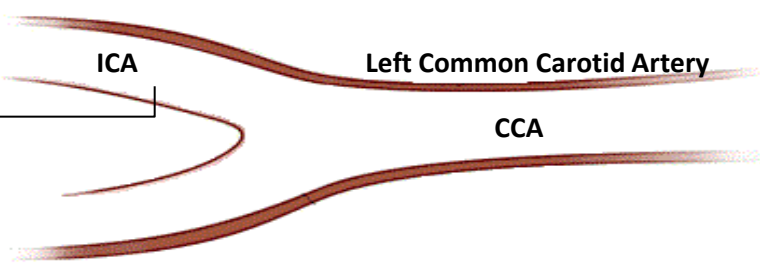
**Patient Name:** WINTER, SHARON  
**DOB:** 9-Mar-59

**Physician:** GALAN  
**Exam Date:** 9-Apr-21

<b>Right</b>	<b>ICA</b>	<b>CCA</b>
<b>*PSV:</b>	<b>108</b>	<b>97</b>
<b>*EDV:</b>	<b>19</b>	<b>23</b>
<b>RICA STENOSIS:</b>	<b>&lt; 20%</b>	



<b>Left</b>	<b>ICA</b>	<b>CCA</b>
<b>*PSV:</b>	<b>66</b>	<b>82</b>
<b>*EDV:</b>	<b>32</b>	<b>22</b>
<b>LICA STENOSIS:</b>	<b>&lt; 20%</b>	



**Left Vertebral Artery**  
**Velocity:** 25  
**Direction:** Antegrade

**Right Vertebral Artery**  
**Velocity:** 26  
**Direction:** Antegrade

**Vertebral Artery**



COMMENT: Dynamic ultrasound scanning of the neck was performed with carotid duplex (Doppler & B-Mode ultrasound) arterial analysis including color flow and spectral analysis; Impression: Normal bilateral carotid duplex ultrasound exam.

Physicians Signature: \_\_\_\_\_



